

**A714-Test slide, Liver cancer tissues  
with corresponding normal tissues**

(formalin fixed)

For research use only

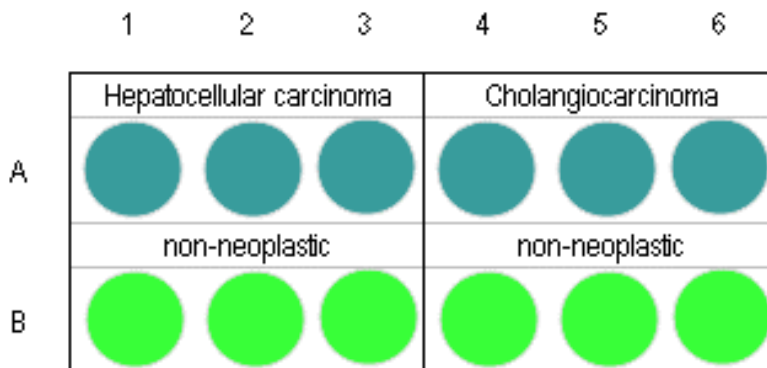
**Specifications:**

- No. of cases: 6
- Tissue type: Test slide, Liver cancer tissues  
with corresponding normal tissues
- No. of spots: 6 spots from each cancer case (6 spots)  
6 non-neoplastic spots (6 spots)
- Total spots: 12
- Corresponding normal tissues with cancers: Yes
- Diameter: 1.0 mm

**Documents:**

- Product specification: layout, summary of tissue spots
- H&E stained images
- Detailed pathological information

**Layout:**



**A714-Test slide, Liver cancer tissues  
with corresponding normal tissues**

(formalin fixed)

For research use only

**Summary of tissue spots**

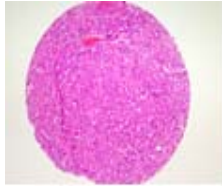
No	Coordinate		Sex	Age	Key word
1	A	1	m	67	Liver: hepatocellular carcinoma
2	B	1	m	67	Non-neoplastic from A1
3	A	2	m	36	Liver: hepatocellular carcinoma
4	B	2	m	36	Non-neoplastic from A2
5	A	3	m	55	Liver: hepatocellular carcinoma
6	B	3	m	55	Non-neoplastic from A3
7	A	4	m	72	Liver: cholangiocarcinoma
8	B	4	m	72	Non-neoplastic from A4
9	A	5	m	64	Liver: cholangiocarcinoma
10	B	5	m	64	Non-neoplastic from A5
11	A	6	m	72	Liver: cholangiocarcinoma
12	B	6	m	72	Non-neoplastic from A6

**A714-Test slide, Liver cancer tissues  
with corresponding normal tissues**

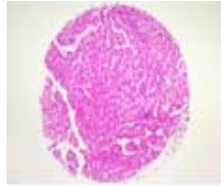
(formalin fixed)

For research use only

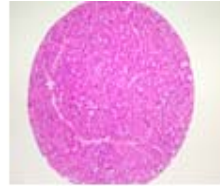
**QC sheet\_LOT#132120507072  
Hematoxylin and Eosin staining**



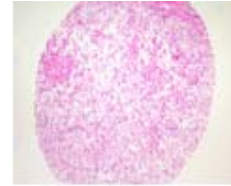
A1



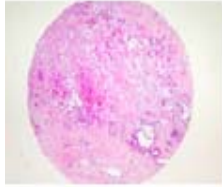
A2



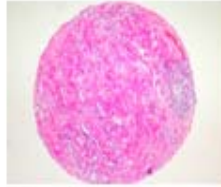
A3



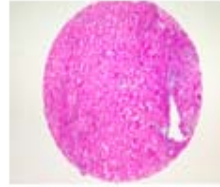
A4



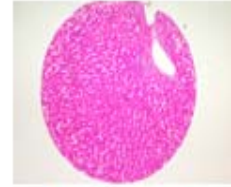
A5



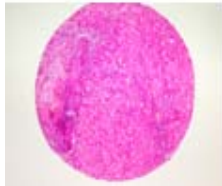
A6



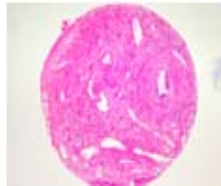
B1



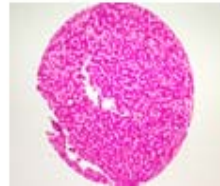
B2



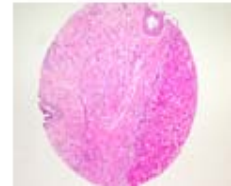
B3



B4



B5



B6

**A714: Test slide, Liver cancer tissues with corresponding normal tissues**

No	Coordinate		Sex	Age	Key word	Histological Diagnosis
1	A	1	m	67	liver: hepatocellular carcinoma	<p>1. Liver, VII segment, segmentectomy: hepatocellular carcinoma, with</p> <ol style="list-style-type: none"> <li>1) size: 5x4.5x4.5cm</li> <li>2) Edmondson grade I to II</li> <li>3) single nodular type with expanding growth</li> <li>4) no necrosis (less than 5% of total volume)</li> <li>5) microvessel invasion</li> <li>6) intact resection margin (safety margin: less than 0.2cm)</li> <li>7) non-neoplastic liver showing chronic hepatitis, B-viral, with mild inflammatory activity (grade II) and cirrhosis (stage IV)</li> </ol> <p>2. Gallbladder, cholecystectomy: free from tumor extension.</p>
2	B	1	m	67	non-neoplastic	non-neoplastic from A1
3	A	2	m	36	liver: hepatocellular carcinoma	<p>1. Liver: hepatocellular carcinoma with</p> <ol style="list-style-type: none"> <li>1) size: 7x7x5.8cm</li> <li>2) Edmondson grade II to III (moderately differentiated)</li> <li>3) single nodular type with encapsulation and expanding growth</li> <li>4) trabecular, macrotrabecular and compact histologic type</li> <li>5) microvascular invasion</li> <li>6) necrosis: more than 80% of total volume</li> <li>7) capsular involvement</li> <li>8) intact intrahepatic resection margin (safety resection margin:3mm)</li> <li>9) non-neoplastic liver showing chronic hepatitis, B-viral, with mild inflammatory activity(grade II) and cirrhosis (stage IV)</li> </ol> <p>2. Gallbladder, cholecystectomy, separately submitted: free from tumor extension.</p>
4	B	2	m	36	non-neoplastic	non-neoplastic from A2

**A714: Test slide, Liver cancer tissues with corresponding normal tissues**

No	Coordinate		Sex	Age	Key word	Histological Diagnosis
5	A	3	m	55	liver: hepatocellular carcinoma	<p>1. Liver, segmentectomy: hepatocellular carcinoma with</p> <ol style="list-style-type: none"> <li>1) size: 3.5x3.2x2.3cm</li> <li>2) histologic type: trabecular type</li> <li>3) Edmondson grade III with perinodal spread</li> <li>4) single nodular type</li> <li>5) vascular invasion</li> <li>6) necrosis: approximately 60% of total volume</li> <li>7) intact hepatic resection margin</li> <li>8) chronic hepatitis, B-viral, with moderate inflammatory activity(grade III) and early cirrhosis (stage III) showing multiple dysplastic nodules</li> </ol> <p>2. Gallbladder, cholecystectomy: no pathological diagnosis</p> <p>3. Soft tissue, separately submitted: fat necrosis with calcification.</p>
6	B	3	m	55	non-neoplastic	non-neoplastic from A3
7	A	4	m	72	liver: cholangiocarcinoma	<p>1. Liver, left lateral segment, segmentectomy: cholangiocarcinoma, moderate to poorly differentiated, peripheral type with</p> <ol style="list-style-type: none"> <li>1) size: 6x5.5x5cm</li> <li>2) vascular invasion</li> <li>3) intact intrahepatic resection margin (safety margin: 0.7mm)</li> <li>4) non-neoplastic liver showing reactive hepatitis</li> </ol> <p>2. Gallbladder, cholecystectomy: free from tumor extension.</p>
8	B	4	m	72	non-neoplastic	non-neoplastic from A4
9	A	5	m	64	liver: cholangiocarcinoma	<p>1. Liver, right lobe, lobectomy: cholangiocarcinoma, moderately differentiated, peripheral type</p> <ol style="list-style-type: none"> <li>1) size: 11.5x9.5x7.0cm</li> <li>2) expanding growth and extensive necrosis</li> <li>3) penetration of hepatic capsule and invasion to soft tissue adjacent to diaphragm</li> <li>4) vascular invasion (but not portal vein)</li> <li>5) intrahepatic metastasis</li> <li>6) intact intrahepatic resection margin and diaphragm</li> <li>7) nonneoplastic liver showing reactive hepatitis</li> </ol> <p>2. Gallbladder, cholecystectomy: free from tumor extension.</p>

**A714: Test slide, Liver cancer tissues with corresponding normal tissues**

No	Coordinate		Sex	Age	Key word	Histological Diagnosis
10	B	5	m	64	non-neoplastic	non-neoplastic from A5
11	A	6	m	72	liver: cholangiocarcinoma	<p>Liver and hepatic duct, trisegmentectomy:                      cholangiocarcinoma, adenocarcinoma, moderately differentiated, hilar type (Klastkin tumor) with</p> <ol style="list-style-type: none"> <li>1) size: 2cm in the greatest dimension</li> <li>2) infiltrative growth</li> <li>3) extension to perihilar soft tissue and liver</li> <li>4) frequent perineural invasion</li> <li>5) involvement at right hepatic resection margin</li> <li>6) intact resection margins of liver and common bile duct</li> <li>7) no metastasis to regional lymph nodes (No.1(0/2) and No.2(0/2))</li> <li>8) non-neoplastic liver showing biliary cirrhosis with marked cholestasis</li> <li>9) chronic cholecystitis without tumor metastasis in gallbladder.</li> </ol>
12	B	6	m	72	non-neoplastic	non-neoplastic from A6