

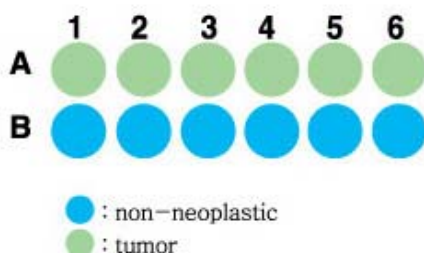
### Specifications:

- No. of cases: 6
- Tissue type: Test slide, lung cancer tissues with corresponding normal tissues
- No. of spots: 1 spot from each cancer case (6 spots)  
6 non-neoplastic spots (6 spots)
- Total spots: 12
- Corresponding normal tissues with cancers: Yes
- Diameter: 1.0 mm

### Documents:

- Product specification: layout, summary of tissue spots
- H&E stained images
- Detailed pathological information

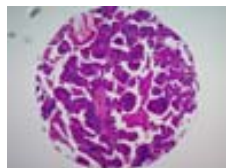
### Layout:



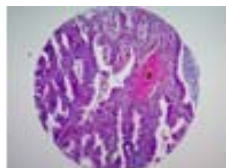
**Summary of tissue spots**

No.	Coordinate	Sex	Age	Organ	Key Word
1	A1	F	75	lung	Papillary adenocarcinoma
2	B1	F	75	lung	Non-neoplastic from A1
3	A2	F	70	lung	Adenocarcinoma
4	B2	F	70	lung	Non-neoplastic from A2
5	A3	M	55	lung	Adenocarcinoma
6	B3	M	55	lung	Non-neoplastic from A3
7	A4	M	44	lung	Squamous cell carcinoma
8	B4	M	44	lung	Non-neoplastic from A4
9	A5	M	65	lung	Squamous cell carcinoma
10	B5	M	65	lung	Non-neoplastic from A5
11	A6	M	63	lung	Squamous cell carcinoma
12	B6	M	63	lung	Non-neoplastic from A6

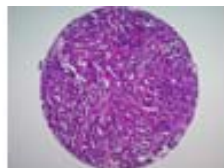
**QC sheet\_LOT#122120404061**  
**Hematoxylin and Eosin staining**



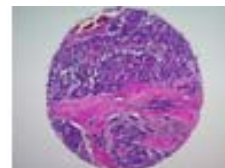
A1



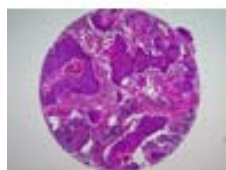
A2



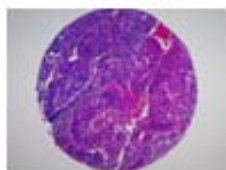
A3



A4



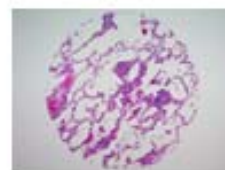A5



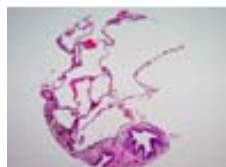A6



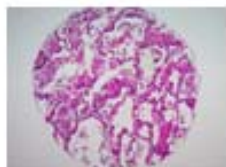B1



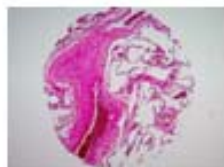B2



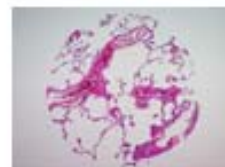B3



B4



B5



B6

**A716: Test slide - Lung cancer tissues with corresponding normal tissues**

No.	Coordinate		Sex	Age	Key Word	Histological Diagnosis
1	A	1	f	75	papillary adenocarcinoma	1. Lung, RUL, lobectomy with MLND: papillary adenocarcinoma, associated with bronchioloalveolar carcinoma 1) tumor size: 4.5x3 cm 2) visceral pleura involvement 3) resection margin, bronchial: free of tumor 4) regional lymph nodes: free of tumor in all nodes (0/21), in detail, regional (0/1), IPL (0/1), hilar (0/2), subcarina I (0/9), lower paratracheal (0/7), peribronchial (0/1)
2	B	1	f	75	non-neoplastic	Non-neoplastic from, A1
3	A	2	f	69	adenocarcinoma	1. Lung, left lower, lobectomy: adenocarcinoma, well differentiated with extension to the visceral pleura 2. Bronchiectasis with aspergillosis (fungal ball) 1) bronchus, resection margin: free of tumor 2) lymph node, separately sent, IPL (0/4), interlobar (0/2), lobar (0/1), para-aortic (0/2), hilar(0/1): free of tumor
4	B	2	f	69	non-neoplastic	Non-neoplastic from, A2
5	A	3	m	53	adenocarcinoma	1. Lung, lobectomy: adenocarcinoma, poorly differentiated, 1) size 2. 5x2. 4 cm 2) extension to the visceral pleura 2. Surrounding lung: emphysematous change 1) resection margin: free of tumor 2) regional lymph node, peribronchial: free of tumor (0/2)
6	B	3	m	53	non-neoplastic	Non-neoplastic from, A3

**A716: Test slide - Lung cancer tissues with corresponding normal tissues**

No.	Coordinate		Sex	Age	Key Word	Histological Diagnosis
7	A	4	m	44	squamous cell carcinoma	<p>1. Lung, right, pneumonectomy: bronchogenic squamous cell carcinoma, poorly differentiated, 1) marked tumor necrosis and vascular permeation 2) tumor extension to the visceral pleura 3) obstructive pneumonitis 4) resection margin, bronchial: free of tumor 5) regional lymph nodes, hilar lymph nodes (2/3), interlobar lymph nodes(1/6), subcarinal lymph nodes (0/4) : (3/13): tumor metastasis in 3 out of 13 lymph nodes</p> <p>2. "Labelled as chest wall": presence of squamous cell carcinoma with marked necrosis</p> <p>3. "Labelled as mediastinal pleura": free of tumor 1) acute nonspecific inflammation with fibrosis</p> <p>*Note: Immunohistochemical stain results: NSE, Chromogranin A, Synaptophysin all focally positive.</p>
8	B	4	m	44	non-neoplastic	Non-neoplastic from, A4
9	A	5	m	65	squamous cell carcinoma	<p>1. Lung, RLL, lobectomy: squamous cell carcinoma, well differentiated, 1) arising from periphery of superior segment 2) focally extension to the visceral pleura 3) resection margin of bronchus: free of tumor 4) lymph nodes, interlobar (0/7) and IPL (0/3): free of tumor in all 10 lymph nodes 5) numerous anthracosilicotic nodules</p>
10	B	5	m	65	non-neoplastic	Non-neoplastic from, A5
11	A	6	m	63	squamous cell carcinoma	<p>1. Lung, left, pneumonectomy: Squamous cell carcinoma, well differentatied with 1) invasion to visceral pleura 2) no lymphovascular invasion 3) anthracosilicotic nodules with calcification and ossification 4) resection margin, bronchial: free of tumor 5) regional lymph nodes, paraesophageal (0/3), subaortic (0/1), AP window (0/1), hilar (0/10): free of tumor in all 15 lymph nodes 6) anthracosilicotic nodules</p>
12	B	6	m	63	non-neoplastic	Non-neoplastic from, A6